

Research Article

Identification of fish anatomopathological injuries from an experimental fish farm in the Peruvian Amazonia

Juan Rondón¹ , César Villanueva¹ , Cielo Llerena²  & Nieves Sandoval³ 

¹Pucallpa Experimental Station, Centro de Investigación IVITA, Universidad Nacional Mayor de San Marcos
Ucayali, Perú

²Histopathology Laboratory, Faculty of Veterinary Medicine and Zootechnics, Universidad Peruana
Cayetano Heredia, Lima, Perú

³Histology, Embryology and Veterinary Pathology Laboratory, Veterinary Medicine School
Universidad Nacional Mayor de San Marcos, Lima, Perú

Corresponding author: Juan Rondón (jrondone@unmsm.edu.pe)

ABSTRACT. This study aimed to identify anatomopathological injuries in sick, moribund, or recently dead fish from an experimental fish farm in the Peruvian Amazonia with a necropsy, direct microscopic, and histopathological examination. The study was carried out at the migratory fish production unit where cachama (*Colossoma macropomum*), pacus (*Piaractus brachypomus*), black prochilodus (*Prochilodus nigricans*), and spotted tiger shovelnose catfish (*Pseudoplatystoma punctifer*) are bred. Furthermore, from the non-migratory fish unit where arapaima (*Arapaima gigas*) and Nile tilapia (*Oreochromis niloticus*) are bred at the fish farm within the Experimental Station of the IVITA Research Center in Ucayali, Peru. Thirty clinical cases distributed in thirteen incidents of diseases observed between January 2013 and June 2014 were evaluated. The tissue macroscopic and microscopic evaluations were performed through necropsies to determine the injuries and the possible causes of mortality. Samples of the skin and gills mucous membrane were collected to identify parasites by direct microscopy, and liver, kidney, and spleen imprints stained with Gram were made to observe the presence of bacteria. Histopathological analyzes of the affected tissues were also performed in some of the evaluated cases. Parasites, mainly trematodes, were found in cachama, protozoa in arapaima, and bacteria suggestive of *Flavobacterium* sp. in spotted tiger shovelnose catfish. Digestive (14/30), respiratory (9/30), and traumatic (3/30) injuries were identified.

Keywords: fish farm; injuries; pathological; necropsy; parasites; Peruvian Amazonia

INTRODUCTION

Traditional fish farming activity in Peruvian Amazonia is most extensive and semi-intensive to intensive farming (BCRP 2017) as a productive alternative development. It depends on the rural and urban population's demands. A variety of species, such as cachama (*Colossoma macropomum*), pacus (*Piaractus brachypomus*), spotted tiger shovelnose catfish (*Pseudoplatystoma punctifer*), black prochilodus (*Prochilodus nigricans*), arapaima (*Arapaima gigas*), among others (García-Dávila et al. 2018) are farmed in a controlled environment. In addition, fish farming represents an alternative to fishing in rivers which is

increasingly limited due to the strong pressure on fishing (FAO 2016).

Despite the Amazonian fish farming being a low percentage in the local production, it has shown an interesting development in recent years (BCRP 2017). Last few years, fish farming in the country has increased (Ríos 2012, Kleeberg 2019); however, it is still low compared to other Latin American countries' development. Consequently, the production system has improved and caused pathological complications emergence of various origins affecting the aquatic species' health and welfare and trade and human health (CFSPH 2011).

Sanitary management is vital in the Amazonian fish farming in natural and artificial environments because the emergence of diseases can cause economic losses and compromise the fish farm's life and survival (FAO 2011). Although mortality rates in semi-intensive fish farming are classified as moderately low to low (Conroy 2006), fish farm optimal management should include evaluation of production parameters (weight, height, feed conversion, and survival percentage) in addition to diagnosis and diseases record (SANIPES 2016).

The fish anatomical pathology is a constant training area for veterinary pathologists. The lack of standardized information in this area often causes errors in the diagnosis due to the lack of identification of pathological injuries or pathological diagnoses (Wolf et al. 2015). Recently, Rey et al. (2020) have proposed standardization of histopathological injuries to allow the characterization of fish diseases and the ichthyopathologists' global consensus about the diagnosis, interpretation, registration, and reporting of the data. Therefore, this study aims at anatomic-histopathological recognition as part of fish farming health.

This research aims to identify anatomopathological injuries in sick, moribund, or recently dead fish from an experimental fish farm in the Peruvian Amazonia with a necropsy, direct microscopic, and histopathological examination.

MATERIALS AND METHODS

Place and time of the research

The fieldwork was conducted in the fish farm of the Experimental Unit of the Veterinary Institute for Tropical and High-Altitude Research (IVITA, by its Spanish acronym) located in the District of Campo Verde, Province of Coronel Portillo, Region of Ucayali (Peru). Two farmed species types were examined; the migratory fish: cachama *Colossoma macropomum*, pacu *Piaractus brachipomus*, and spotted tiger shovelnose catfish *Pseudoplatystoma punctifer*; the non-migratory fish: arapaima *Arapaima gigas* and Nile tilapia *Oreochromis niloticus*.

The direct macroscopic and microscopic examinations were performed in a conditioned area located in each rearing unit of the fish farm. The histopathological examination was performed in the Laboratory of Histology, Embryology and Veterinary Pathology, School of Veterinary Medicine, National University of San Marcos, Lima (Peru). The study was carried out between January 2013 and June 2014.

Fish monitoring and collection

A specimen collection was carried out when clinical issues or diseases emerged in the rearing unit's ponds, tanks, or trays, as described by the FAO (2011). The main clinical signs studied were panting, erratic swimming, stability problems in the water, rubbing against the pond's edge, and moving away from the shoal, specifically described according to the incidence (Table 1). The samples of specimens were sick, moribund, or recently dead, as described by Eiras et al. (2006).

The collected fish samples presented one or several specimens with each incident disease or evident clinical sign. The captured live fish were anesthetized by immersion in an infusion of cloves (*Syzygium aromaticum*) (3 g L⁻¹), following the procedure of Millán-Ocampo et al. (2012) with some modifications. After immobilization, a medullary cut was made in the anterior dorsal area at the level of the caudal edge of the operculum, with dissection scissors for small fish or a scalpel for large fish (Conroy 2006).

Pathological examination

Necropsy and direct microscopic examination

The recognition and description of the pathological injuries during the necropsy examination were done according to Leatherland (2010) and Noga (2010). In case of infectious process suspicion, imprints of secretions (skin mucus) or tissues (liver, spleen, and kidney) were taken, and Gram stain was applied to determine possible bacterial species, as described by Conroy (2006). Because the cases were evaluated in person in situ and far from a microbiological diagnostic laboratory, bacteriological isolation was not performed.

Parasitological and histopathological examination

Parasites were ruled out by taking skin mucus or extensions of small sections of gills, liver, intestines, and muscle and adding 1-2 drops of saline to the extension for observation of trematodes or 1-2 drops of Lugol's iodine to observe protozoans, as described by Conroy (2006). Samples of liver, spleen, stomach, intestine, and muscle tissues were taken from the fish to evaluate histopathological injuries. All samples were preserved in 10% formalin, in a ratio of 1:10, according to Noga (2010). Samples were collected from fish with apparent injuries. In the case of post-larvae of *A. gigas* 1.5 cm long, they were collected from all the specimens. Conventional histology processing was performed for formalin-fixed tissues; tissue sections were cut at 5 μ thickness, spread on histological slides, and stained with hematoxylin and eosin. The slides were observed under an optical light microscope with

Table 1. Characteristics of the fishes (cachama (*Colossoma macropomum*), pacus (*Piaractus brachypomus*), spotted tiger shovelnose catfish (*Pseudoplatystoma punctifer*) and arapaima (*Arapaima gigas*)) collected for the macroscopic and microscopic examination *in situ* in the IVITA Experimental Station fish farm in Pucallpa, Ucayali, Peru. *A histopathological study was conducted.

Incident number	Name	Approximated age	Clinical observed signs prior to sampling	Rearing place
1	Cachama	3 months (1 initial juvenile)	Erratic swimming and shoal isolation	Earthen pond
2	Cachama	6 months (1 juvenile)	Erratic swimming	Earthen pond
3	Cachama	3 years (1 reproductively active juvenile)	Erratic swimming and lack of stability in water	Earthen pond
4	Cachama	3 years (1 reproductively active juvenile)	Erratic swimming and lack of stability in water	Earthen pond
5	Cachama*	6 years (1 reproductively active)	Erratic swimming and lack of stability in water	Earthen pond
6	Pacus	65 days (9 fry fish)	Gasping	Fiberglass tank
7	Spotted tiger shovelnose catfish*	2.5 months (1 fry fish - juvenile)	Lack of stability in water	Fiberglass tank
8	Spotted tiger shovelnose catfish*	7 months (1 juvenile)	Lack of stability in water	Fiberglass tank
9	Spotted tiger shovelnose catfish	3 years (1 reproductively active)	Erratic swimming and lack of stability in water	Earthen pond
10	Spotted tiger shovelnose catfish *	3.5 years (1 reproductively active)	Erratic swimming and lack of stability in water	Earthen pond
11	Arapaima*	9-10 days (5 postlarvae)	Erratic swimming and shoal isolation	Fish trays
12	Arapaima*	3 weeks (6 fry fish)	Erratic swimming and shoal isolation	Fish trays
13	Arapaima	5 around years (1 reproductively active)	Found at the bottom of the pond	Earthen pond

magnifications of 10x, 40x, and 100x to determine pathological injuries.

Data analysis

A descriptive statistic was performed to outline the lesion type frequency in the migratory fish and non-migratory fish groups.

RESULTS

The necropsy examination of 30 fish was carried out in the two units of the fish farm, detecting 13 incidents of clinical problems. Of the fish examined; 15 were sacrificed, coming from ponds (4) and tanks (11), 14 fish died a few minutes after collection, these came from ponds (3) and tanks or trays (11), and finally, one was dead for a few hours and was pulled from a pond. According to the cultured specimen, 18 fish were collected in the migratory unit (five cachamas *Colossoma macropomum*, nine pacus *Piaractus brachypomus*, and four speckled tiger shovel catfish *Pseudoplatystoma punctifer*), and 12 arapaimas *Arapaima gigas* were selected in the non-migratory fish unit (one adult and 11 initial stages). Nile tilapia

Oreochromis niloticus specimens were not collected during the examination period. The characteristics of the selected fish in each incident are described (Table 1).

Tissue samples were collected from seven specimens, [one adult cachama, three spotted tiger shovel catfish (one adult and two hatchlings), and three arapaimas (one fry and two postlarvae)], for histopathological examination and to obtain further information that complements macroscopic study and direct microscopic examination. On the other hand, the incidence of clinical signs related to the disease occurred in different hatcheries (pond, tank, or jar) and at different times, except for incidents 3 and 4 in cachama and 9 and 10 in spotted tiger shovelnose catfish, which, occurred in the same pond (Table 1).

Macroscopic injuries were found in most of the evaluated specimens except for one juvenile of cachama and the initial stages of *A. gigas* (Table 2). In cachamas, apart from digestive and trauma injuries, parasites of the Dactylogyridae family were found in the gills of juveniles and adults. In pacus, the macroscopic injuries were very severe and compatible with the respiratory problem (Table 2). In spotted tiger

Table 2. Macroscopic and direct microscopy injuries found in specimens (cachama (*Colossoma macropomum*), pacus (*Piaractus brachipomus*), spotted tiger shovelnose catfish (*Pseudoplatystoma punctifer*) and arapaima (*Arapaima gigas*)) from the migratory fish unit and non-migratory fish of the IVITA Experimental Station fish farm in Pucallpa, Ucayali, Peru.

Species	Age	Macroscopic injuries
Cachama	3-6 years (reproductive active) (3 fish)	Two had hemorrhages on the serous parts of the gonads, and blood clots in the coelomic cavity (Fig. 1), and one presented paleness and a friable liver (a liver sample was taken for histopathology). Slight to the moderate presence of monogenous trematodes of the family Dactylogyridae in gills.
	3-6 months (2 fish)	Only one presented skin ulcers on the dorsal area of the trunk. Slight presence of monogenous trematodes of the family Dactylogyridae in gills.
Pacus	65 days (9 fry fish)	Showed vascular congestion on the gills' epithelial layers, the oral cavity's opening, and congestion on the abdomen skin in three of them.
Spotted tiger shovelnose catfish	3-3.5 years (reproductive active) (2 fish)	Showed ascites with liver lacerations (Fig. 2), with multiple pale beige-colored nodules (n = 3) of 0.5 cm in diameter on the surface of one liver lobe. One case showed friable liver.
	2.5 months (fry fish - juvenile) (2 fish)	Showed a serosa inflammation on the stomach's back and intestine's front portions.
Arapaima	Adults (1 fish)	Showed ulceration and necrosis of the caudal fin, bleeding areas in the gastric and intestine mucosa, alternated with post-mortem changes (pseudomelanosis).
	Fry fish (11 fish)	Four larvae showed a moderate presence of gases in the digestive system, intestine mucosa alterations, and areas of slight blood congestion on the edge of the gill membranes, whereas, in one individual, there were no apparent injuries; the stomach and intestines of one fry fish with injuries was collected for a histopathology study. The six postlarvae did not show apparent injuries, and two complete specimens were collected for the histopathology examination.

shovelnose catfish, direct microscopy and histopathology injuries showed mainly digestive problems, and filamentous bacteria were found in liver blood vessels compatible with *Flavobacterium* sp. (Table 3). Finally, no apparent injuries were found on direct microscopy in the initial stages of arapaima (Table 2). However, injuries were detected at the digestive level on histopathological examination and parasitic stages of *Microsporidium* sp. in the enterocytes of the intestinal mucosa (Table 3).

Digestive injuries appeared in 46.7% (14/30) of the cases, respiratory injuries in 30% (9/30), and traumatic injuries in 10% (3/30). No evidence of macroscopic injuries was found in 13.3% (4/30) cases. Some injuries found are shown (Figs. 1-2). The total distribution of injuries and mortality events in each culture unit is described (Fig. 3). Digestive injuries were more frequent in non-migratory fishes than in migratory fishes, and respiratory injuries were more frequent in migratory fishes than in non-migratory fishes. Finally, traumatic injuries were rare in migratory fishes.

DISCUSSION

The mortality in semi-intensive Amazonian fish farming is relatively low; likewise, the risk of disease

emergence is moderate. It is more frequently reported due to farming management and parasitosis (Conroy 2006). However, there is a lack of studies on monitoring and identifying pathological injuries in semi-intensively fish farming in the Peruvian Amazonia; only Ramos et al. (2016) researched the emergence of histopathological injuries and bacteria in bacteria semi-intensively farming of cachamas in the Amazonia.

This work collected 30 specimens of different Amazonian fish species from 13 incidents of clinical health problems during 18 months of evaluation (Tables 1-2). These events involved a larger fish population; however, the study aimed to identify the types of injuries for health issues. It was difficult to detect clinical signs in the fishponds due to the water turbidity and eutrophication, and consequently, the collection was affected. Khan & Mohammad (2013) also reported eutrophication problems. For this reason, the tanks or trays were easier to evaluate due to the reduced volume of water they contained.

In adult cachamas *Colossoma macropomum*, the blood clots findings in the coelomic cavity and gonads (Fig. 1) demonstrated hemorrhages caused by traumatic events; these injuries due to traumatic events are also reported by Rankin et al. (2017). On the other hand,

Table 3. Histopathological injuries in fishes (cachama (*Colossoma macropomum*), spotted tiger shovelnose catfish (*Pseudoplatystoma punctifer*) and arapaima (*Arapaima gigas*)) from the migratory fish unit and non-migratory fish of fish farm IVITA Experimental Station in Pucallpa, Ucayali, Peru.

Species	Age	Samples	Histopathological finding
Cachama	6 years (reproductive active)	Liver	Severe vacuole degeneration and fatty hepatocytes, loss of liver tissue architecture showing multifocal necrosis, congestion of interlobular veins.
Spotted tiger shovelnose catfish	3 years (reproductive active)	Liver and spleen	In the liver, a slight hydropic degeneration of the vesicle, filamentous structures compatible with <i>Flavobacterium</i> sp. in blood vessels, and slight autolysis.
Spotted tiger shovelnose catfish	2.5 months (fry fish - juvenile)	Stomach and intestines	In the intestines, hyperplasia of the mucous membranes and thickening of the intestinal submucosa.
Spotted tiger shovelnose catfish	7 months (juvenile)	Stomach, intestines, and liver	Hyperplasia of the mucous membranes and the intestinal and muscular submucosa thickening in the intestines. In the liver, the presence of filamentous bacteria potentially compatible with <i>Flavobacterium</i> specimen in the liver blood vessels.
Arapaima	3 weeks (fry fish)	Stomach, intestines, and muscle	In the intestines, the presence of mononuclear meronts and division of <i>Microsporidium</i> sp. in the mucosal enterocytes.
Arapaima	9-10 days (2 postlarvae)	Stomach, intestines, and muscle	In intestines and muscle, a significant presence of mononuclear meronts and division of <i>Microsporidium</i> sp. in the mucosal enterocytes and among the bundles of muscle fibers.

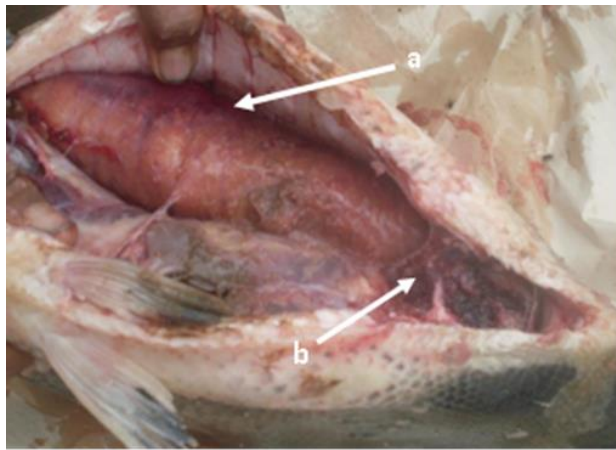


Figure 1. Hemorrhage in the coelomic cavity and gonads of an active reproductive cachama (*Colossoma macropomum*). a) Cranial direction, hemorrhage in the lateral part of the cavity that involves the ovary towards the membranes of the coelomic cavity, b) caudal direction, blood clots in the serous on the back portion of the abdomen.

histopathological injuries at the liver level in a cachama dosed with a non-conventional synthetic hormone product for spawning induction suggest the influence of a toxic process by foreign agents (Table 3); this is also described by Wolf & Wolfe (2005). Additionally, superficial ulcers in early juvenile cachama on the external skin of the trunk are traumatic injuries, as des-

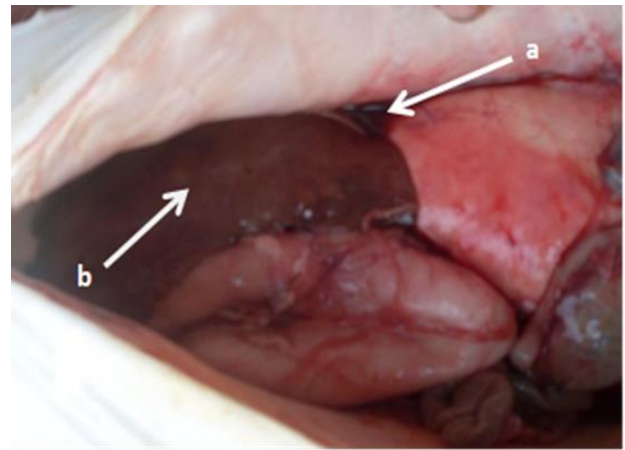


Figure 2. Ascites in adult spotted tiger shovelnose catfish (*Pseudoplatystoma punctifer*). a) Caudal direction, presence of liquid in the coelomic cavity, b) cranial direction, and presence of pale beige-colored nodules on the surface of one liver lobe.

cribed by Collins (2000), suggesting the constant rubbing effect of the fish due to high densities or predator's intervention such as herons (*Ardea* specimen) which attack them from 15 days age. These incidents by predators usually occur in earlier stages of breeding by immature forms of the order Odonata (Ramírez 2010). It has occasionally been observed in areas close to the edges of the ponds (FONDEPES 2021). It is worth mentioning that no affected specimens

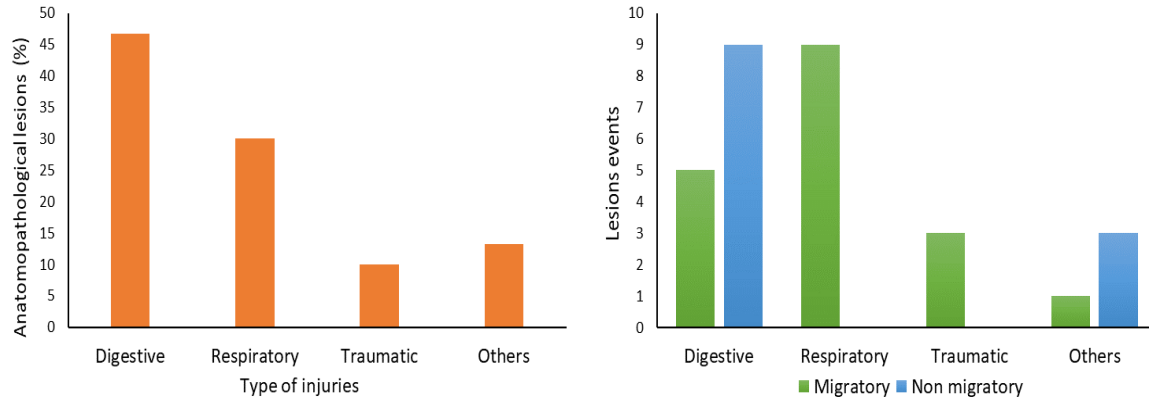


Figure 3. Total percentages of the type of anatomopathological injuries and mortality-event injuries in the fish farms units of IVITA Experimental Station in Pucallpa, Ucayali, Peru.

were obtained from postlarvae or fry planted in ponds with vegetation.

The gills infested by monogenean parasites of adult and juvenile cachama were mild to moderate. Vargas (2015) and Rondón et al. (2021a) describe monogeneans commonly found on cachamas' gills in fish farms in the Peruvian Amazonia. Godoi (2011) and Negreiros et al. (2021) also found parasites in two fish farms in Brazil. It should be noted that the good quality of water contributes to reducing the parasite load enough not to affect the fish's health. Thatcher & Moravec (2006) and Rondón et al. (2021b) mention that the failure in water quality could exacerbate this parasitosis, generating injuries at the tissue level of gills due to the deficit in oxygen consumption by the gill plates. However, Wolf et al. (2015) mention that gills have high regenerative power. It should be noted that severe infestation by monogeneans can generate injuries such as hyperplasia of primary lamellae, inflammatory response, necrosis, edema, degenerative changes, epithelial dysplasia, pillar cell rupture, and telangiectasia (Aragort et al. 2002, Clarke et al. 2012, Gjesin et al. 2019).

Despite only some pacu *Piaractus brachipomus* fry were examined, these specimens' necropsy revealed macroscopic injuries (rigor mortis, gill congestion, opening of the oral cavity, and upward twisting of the head) and hypoxia with respiratory dysfunction as a result of lack of oxygen in the water, especially in acute processes (Conroy 2006). Fish can adapt to the progressive decrease in oxygen in the water (Braz-Mota & Almeida-Val 2021); however, acute hypoxia due to lack of water flow in the collection tank prior to dispatch can cause fingerlings severe damage.

The adult spotted tiger shovelnose catfish *Pseudoplatystoma punctifer* injuries were found after the

artificial reproductive management, suggesting deficiencies in the process (Fig. 2). These injuries found in the coelomic cavity and viscera coincide with what was reported by Collins (2000). Additionally, the bulging of the abdomen and ascites in adult spotted tiger shovelnose catfish have also been reported by Paredes et al. (2011). On the other hand, the compatible forms of *Flavobacterium* sp. found in the liver's blood vessels suggest the development of a septicemic process (Loch & Faisal 2015). This bacterium has also been reported in fish of the genus *Pseudoplatystoma* (Barony et al. 2015). In fingerlings and juveniles, macroscopic injuries were found in the stomach, and hyperplasia was found in the intestinal mucosa. These injuries suggest a dysfunction of the digestive system. The increase in absorption capacity of the cell layers is possibly due to a change in feeding, which could change the tissue development of the digestive system (Gisbert et al. 2014). This finding is also described by Palacios (2015) in another Amazonian fish species.

The greater number of respiratory injuries in fish is due to the greater number of pacu affected by deficiency in water circulation and oxygenation in the collection tanks. In this group of species, the high incidence of digestive lesions was demonstrated in addition to the high incidence of respiratory and traumatic lesions (Tables 2-3). The adult arapaima *Arapaima gigas* injuries found were predominantly digestive alterations (Table 3).

In non-migratory fish, besides lesions observed at the histopathological level in larvae and postlarvae, most of the lesions at the digestive level are similar to those reported by García (2015), which may be related to stress-generating mechanisms due to poor water quality, lack of recycling and constant cleaning of excreta and deficiencies in fish management (Gomez

2007) added to inadequate feeding (Padilla et al. 2003) and concurrent infectious agents also found in this study.

Although the temperature, oxygen, and pH parameters were not severely altered, other parameters, such as ammonium, nitrites, and nitrates of the water in the trays were not measured because Amazonian fish can be very sensitive to changes in water quality, as shown by Souza-Bastos et al. 2015. On the other hand, it is common practice to isolate bacteria in internal organs, and fungi from the skin of healthy arapaima fry and juveniles reared in captivity in the Peruvian Amazonia as they can become secondary pathogens of bacterial and viral origin or in traumatic skin injuries (Serrano et al. 2014, Murrieta et al. 2020).

No Nile tilapia *Oreochromis niloticus* specimens were found with signs compatible with clinical issues. One adult specimen had an abscess in the middle area of the trunk. However, this case was not examined because the specimen had died many hours ago, and it was in the decomposition stage, so it was not included in the study. In the Amazon, Nile tilapia pathogens have been reported, such as the tilapia lake virus in the region of San Martín (Pulido et al. 2019), but in the semi-intensive farming of these exotic species, the diseases are not frequently reported.

The eutrophication of the water, characteristic of this type of farming, can also generate oxygenation problems in the ponds (Murrieta et al. 2021). For this reason, the balance of environmental variables or the water quality management in the fish farming system prevents the appearance of diseases (Bhatnagar & Devi 2013). Health problems could result from a series of factors that converge and act directly on the fish farm. They could trigger stress, alter the endocrine activity, reduce the immune response of the skin, mucous, and organs (Roberts 2012), and exacerbate saprophytic agents or pathogens in an aquatic environment (Anders & Yoshimizu 1994). Consequently, in incidents where only one specimen was found infected, this may be either a failure in the handling of the specimen, in the case of traumatic injuries (but not by a predator), or individual susceptibility to handling conditions in case of other types of injuries (respiratory and digestive).

The macroscopic injuries were considered for a presumptive diagnosis and were confirmed with microscopic or histopathological examinations. Although the anatomopathological injuries help identify a management issue, some other diagnostic tools are important and shall be executed to carry out a constant and comprehensive health assessment of fish farms (FAO 2011). The work field conditions did not allow applying a bacteriological rule-out procedure. However, it is important to mention that saprophytic

bacteria commonly found in Amazonian fish shall not affect unless there is a stress condition of diverse etiology (Buller 2015).

Although the grouping of pathological injuries is classified as respiratory, digestive, traumatic, or others, it is general (Fig. 3). These factors can trigger other types of interrelated injuries, so their recognition could contribute to the application of a follow-up in the deficiencies of rearing management and implementing preventive measures against sanitary incidences contributing to regional fish farming. For this reason, disease prophylaxis is also the provision of good rearing conditions, including optimal water quality and low-stress levels (Segner et al. 2019)

The present is the first onsite study in the Peruvian Amazon region about health problems monitoring executed onsite in an experimental fish farm with semi-intensive fish farming management supported with diagnostic tools such as necropsies, direct microscopic examinations, and histopathology. This basic information could be a starting point to objectively understand and prevent management problems in extensive and semi-intensive fish farms in the Region of Ucayali to progressively optimize management systems in regional fish farming.

ACKNOWLEDGEMENTS

We thank all the staff of the Experimental Research Centre IVITA in Pucallpa of the School of Veterinary Medicine of the National University of San Marcos who collaborated with this research work. We also thank Miguel Carrion for his support in improving the English version of the manuscript.

REFERENCES

- Anders, K. & Yoshimizu, M. 1994. Role of viruses in the induction of skin tumours and tumour-like proliferations of fish. *Diseases of Aquatic Organisms*, 19: 215-232. doi: 10.3354/DAO019215
- Aragort, W., Morales, G., León, E., Pino, A.L., Guillén, A. & Silva, M. 2002. Patologías asociadas a monogeneos branquiales en cachama bajo cultivo. *Veterinaria Tropical*, 27: 75-85. doi: 10.1590/S0044-596720130-00100 013
- Banco Central de Reserva del Perú (BCRP). 2017. Potencial acuícola en el Perú. [<http://www.bcrp.gob.pe/docs/Publicaciones/Revista-Moneda/moneda-172/moneda-172-07.pdf>]. Reviewed: December 19, 2020.
- Barony, G.M., Tavares, G.C., Assis, G.B.N., Luz, R.K., Figueiredo, H.C.P. & Leal, C.A.G. 2015. New hosts and genetic diversity of *Flavobacterium columnare* isolated

- from Brazilian native species and Nile tilapia. *Diseases of Aquatic Organisms*, 117: 1-11. doi: 10.3354/dao02931
- Bhatnagar, A. & Devi, P. 2013. Water quality guidelines for the management of pond fish culture. *International Journal on Environmental Sciences*, 3: 1980-2009. doi: 10.6088/ijes.2013030600019
- Braz-Mota, S. & Almeida-Val, V.M.F. 2021. Ecological adaptations of Amazonian fishes acquired during evolution under environmental variations in dissolved oxygen: a review of responses to hypoxia in fishes, featuring the hypoxia-tolerant *Astronotus* spp. *Journal of Experimental Zoology*, 335: 771-786. doi: 10.1002/jez.2531
- Buller, N.B. 2015. Bacteria from fish and other aquatic animals. A practical identification manual. CABI, London.
- Center for Food Security and Public Health (CFSPH). 2011. Módulo 15: bioseguridad y prevención de enfermedades en la acuicultura. [http://www.cfsph.iastate.edu/pdf-library/Acreditacion-Veterinaria/NVAP-Mod-15-AQBIO.pdf]. Reviewed: October 23, 2020.
- Clarke, E., Harms, C.A., Law, J.M., Flowers, J.R., Williams, V.N., Ring, B.D., et al. 2012. Clinical and pathological effects of the polyopisthocotylean monogenean, *Gamacallum macroura* in white bass. *Journal of Aquatic Animal Health*, 24: 251-257. doi: 10.1080/08997659.2012.713889
- Collins, R. 2000. Principios de diagnóstico de enfermedades. In: Brown, L. (Ed.). *Acuicultura para veterinarios*. Acibia, Zaragoza, pp. 71-94.
- Conroy, G. 2006. Principales enfermedades en peces de cultivo de la Amazonía. Procedimientos básicos para el reconocimiento y diagnóstico de las enfermedades y parásitos de los peces. FAO, Rome.
- Eiras, J., Takemoto, R.M. & Pavanelli, G.C. 2006. Métodos de estudo e técnicas laboratoriais em parasitologia de peixes. Eduem, Maringá.
- Fondo Nacional de Desarrollo Pesquero (FONDEPES). 2021. Manual de cultivo de gamitana. En ambientes convencionales. [https://www.fondepes.gob.pe/src/manuales/Manual-de-Cultivo-de-Gamitana.pdf]. Reviewed: March 13, 2021.
- Food and Agriculture Organization (FAO). 2011. Manual básico de sanidad piscícola. FAO, Rome.
- Food and Agriculture Organization (FAO). 2016. El estado mundial de la pesca y la acuicultura. Cumplir los objetivos del desarrollo sostenible. FAO, Rome.
- García J.L. 2015. Caracterización histopatológica de lesiones en alevines de paiche (*Arapaima gigas*) en una piscigranja de la región Ucayali-Perú. Veterinary Medicine Thesis, Universidad Nacional Mayor de San Marcos, Lima.
- García-Dávila, C.R., Sánchez-Riveiro, H., Flores-Silva, M.A., Mejía de Loayza, J.E., Angulo-Chávez, C.A.C., Castro-Ruiz, D., et al. 2018. Peces de consumo de la Amazonía Peruana. Instituto de Investigaciones de la Amazonía Peruana, Iquitos.
- Gisbert, E., Moreira, C., Castro-Ruiz, D., Oztürk, S., Fernández, C., Gilles, S., et al. 2014. Histological development of the digestive system of the Amazonian pimelodid catfish *Pseudoplatystoma punctifer*. *Animal*, 8: 1765-1776. doi: 10.1017/s1751731114001797
- Gjessing, M.C., Steinum, T., Olsen, A.B., Lie, K.I., Tavnorpanich, S., Colquhoun, D.J. & Gjevre, A.G. 2019. Histopathological investigation of complex gill disease in sea farmed Atlantic salmon. *Plos One*, 14: e0222926. doi: 10.1371/journal.pone.0222926
- Godoi, M. 2011. Taxonomía e ecología da fauna parasitária de *Colossoma macropomum* (Cuvier, 1818) (Characidae) criados em tanques no município de Rolim de Moura, RO. Ph.D. Thesis, Universidad Federal de Rondônia, Porto Velho.
- Gomes, L.C. 2007. Physiological responses of pirarucu (*Arapaima gigas*) to acute handling stress. *Acta Amazónica*, 37: 629-633. doi: 10.1590/s0044-59672007000400019
- Khan, M.N. & Mohammad, F. 2013. Eutrophication: challenges and solutions. In: Ansari, A.A. & Gill, S.S. (Eds.). *Eutrophication: causes, consequences and control*. Springer, Berlin, pp. 1-15.
- Kleeberg, H.F. 2019. Productividad y competitividad del sector acuícola en el Perú. CIEPLAN, Santiago.
- Leatherland, J.F. 2010. Introduction: diagnostic assessment of non-infectious disorders. In: Woo, P.T. (Ed.). *Fish diseases and disorders*. CABI, London, pp. 1-18.
- Loch, T.P. & Faisal, M. 2015. Emerging flavobacterial infections in fish: a review. *Journal of Advanced Research*, 6: 283-300. doi: 10.1016/j.jare.2014.10.009
- Millán-Ocampo, L., Torres-Cortés, A., Marín-Méndez, G.A., Ramírez-Duart, W., Vásquez-Piñeros, M.A. & Rondón-Barragán, I.S. 2012. Concentraciones anestésicas del eugenol en peces escalares (*Pterophyllum scalare*). *Revista de Investigaciones Veterinarias del Perú*, 23: 171-181. doi: 10.15381/rivep.v23i2.897
- Murrieta, M.G., Nobre, P.J. & Yunis, A.J. 2020. Principales problemas sanitarios y enfermedades parasitarias en la crianza de paiche *Arapaima gigas* en la Amazonía. Instituto de Investigaciones de la Amazonía Peruana, Iquitos.
- Murrieta, M.G.A., Satalaya-Arellano, H., Ramírez-Chirinos, C.S. & Rodríguez-Chu, L.A. 2021. Mortality of black-band myleus (*Myloplus schomburgkii*) due to poor water quality associated with overpopulation of duckweeds in a culture pond in the Peruvian Amazonia.

- Folia Amazónica, 30: 107-112. doi: 10.24841/fa.v30i1.543
- Negreiros, L.P., Neves, L.R. & Tavares-Dias, M. 2021. Parasites in *Leporinus macrocephalus* (Anostomidae) of four fish farms from the western Amazon (Brazil). *Anais da Academia Brasileira de Ciências*, 93: e20190988. doi: 10.1590/0001-3765202120190988.
- Noga, E.J. 2010. Fish disease: diagnosis and treatment. Wiley-Blackwell, Iowa.
- Padilla, P., Ismiño, R., Alcántara, F. & Tello, S. 2003. Producción y manejo de alevinos de paiche en ambientes controlados. Seminario taller internacional de manejo de paiche o pirarucu, Instituto de Investigaciones de la Amazonía peruana, Iquitos, pp. 125-141.
- Palacios, H.S., Sandoval, C.N., Bueno, M.C. & Manchego, S.A. 2015. Estudio microbiológico e histopatológico en peces tetra neón (*Paracheirodon innesi*) de la Amazonía Peruana. *Revista de Investigaciones Veterinarias del Perú*, 26: 469-483. doi: 10.15381/rirep.v26i3.11176
- Paredes, D., Rebaza, C. & Oliva, R. 2011. Patología e identificación bacteriológica preliminar en la mortalidad asociada con un síndrome ascítico en doncella *Pseudoplatystoma fasciatum*. *Folia Amazónica*, 20: 23-27. doi: 10.24841/fa.v20i1-2
- Pulido, L.L.H., Chío, M.M., Chaparro, A.L.H., Dong, H.T. & Senapin, S. 2019. Tilapia lake virus (TiLV) from Peru is genetically close to the Israeli isolates. *Aquaculture*, 510: 61-65. doi: 10.1016/j.aquaculture.2019.04.058
- Ramírez, A. 2010. Odonata. *Revista de Biología Tropical*, 58: 97-136.
- Ramos, E.F., Sandoval, C.N., Morales, C.S., Contreras, S.G. & Manchego, S.A. 2016. Lesiones histopatológicas y aislamiento bacteriológico en gamitanas (*Colossoma macropomum*) aparentemente sanas. *Revista de Investigaciones Veterinarias del Perú*, 27: 188-195. doi: 10.15381/rirep.v27i1.11460
- Rankin, P.S., Hannah, R.W., Blume, M.T.O., Miller-Morgan, T.J. & Heidel, J.R. 2017. Delayed effects of capture-induced barotrauma on physical condition and behavioral competency of recompressed yelloweye rockfish, *Sebastes ruberrimus*. *Fisheries Research*, 186: 258-268. doi: 10.1016/j.fishres.2016.09.004
- Rey, L.A., Asín, J., Ruiz, I., Lujan, L., Iregui, C.A. & De Blas, I. 2020. A proposal of standardization for histopathological injuries to characterize fish diseases. *Reviews in Aquaculture*, 12: 2304-2315. doi: 10.1111/raq.12435
- Ríos, L.L. 2012. Estado de la acuicultura en el Perú. *Revista AquaTIC*, 37: 99-106.
- Roberts, R.J. 2012. Fish pathology. Wiley-Blackwell, Oxford.
- Rondón, E.J., Villanueva, C.C., Del Águila, L.R. & Sandoval, C.N. 2021a. Frecuencia y carga parasitaria en branquias de alevinos de gamitana (*Colossoma macropomum*) mediante exámenes directos en tres establecimientos piscícolas de Ucayali, Perú. *Revista de Investigaciones Veterinarias del Perú*, 32: e20010. doi: 10.15381/rirep.v32i2.20010
- Rondón, E.J., Villanueva, C.C., Gavidia, C.C. & Puicón, N.V. 2021b. Evolución de la dactilogirrosis (monogéneos) en branquias de alevinos de gamitana (*Colossoma macropomum*) en dos medios de crianza: acuático artificial y semi-natural. *Revista de Investigaciones Veterinarias del Perú*, 32: e20015. doi: 10.15381/rirep.v32i2.20015
- Organismo Nacional de Sanidad Pesquera (SANIPES). 2016. Guía fiscalización pesquera y acuícola. Ministerio de la Producción, Lima. [http://www.sanipes.gob.pe/normativas/6_GuiadeFiscalizacionPesquerayAcuicola.pdf]. Reviewed: July 7, 2020.
- Segner, H., Reiser, S., Ruane, N., Rösch, R., Steinhagen, D. & Vehanen, T. 2019. Welfare of fishes in aquaculture. *FAO Fisheries and Aquaculture Circular*, 1189: 1-18.
- Serrano, E., Castro, V., Quispe, M., Casas, G. & León, J. 2014. Aislamiento de bacterias y hongos en tejidos de paiche (*Arapaima gigas*) criados en cautiverio. *Revista de Investigaciones Veterinarias del Perú*, 25: 117-122. doi: 10.15381/rirep.v25i1.8477
- Souza-Bastos, L.R., Val, A.L. & Wood, C.M. 2015. Are Amazonian fish more sensitive to ammonia? Toxicity of ammonia to eleven native species. *Hydrobiologia*, 789: 143-155. doi: 10.1007/s10750-015-2623-4
- Thatcher, V.E. & Moravec, F. 2006. Parásitos de peces amazónicos. PENSOFT, Moscow.
- Vargas, M., Sandoval, N., Casas, E., Pizango, G. & Manchego, A. 2015. Lesiones histopatológicas asociadas a la presencia de parásitos en branquias de gamitana (*Colossoma macropomum*) juveniles criadas en forma semi intensiva. *Revista de Investigaciones Veterinarias del Perú*, 26: 577-586. doi: 10.15381/rirep.v26i4.11222
- Wolf, J.C. & Wolfe, M.J. 2005. A brief overview of nonneoplastic hepatic toxicity in fish. *Toxicologic Pathology*, 33: 75-85. doi: 10.1080/01926230590890187
- Wolf, J.C., Baumgartner, W.A., Blazer, V.S., Camus, A.C., Engelhardt, J.A., Fournie, J.W., et al. 2015. Noninjuries, misdiagnoses, missed diagnoses, and other interpretive challenges in fish histopathology studies. *Toxicologic Pathology*, 43: 297-325. doi: 10.1177/0192623314540229

Received: July 5, 2021; Accepted: May 6, 2022