

Short Communication

First report of synophthalmia and leucism in a bull shark (*Carcharhinus leucas*) embryo from the southeastern Gulf of Mexico

Armando T. Wakida-Kusunoki¹ , Vicente Anislado-Tolentino²  & Luis Fernando Del Moral-Flores³ 

¹Centro Regional de Investigación Acuícola Pesquera de Yucalpetén, Instituto Nacional de Pesca y Acuicultura Yucalpetén, Yucatán, México

²Grupo de Investigadores Libres Sphyrna, Querétaro, México

³Laboratorio de Zoología, Facultad de Estudios Superiores Iztacala
Universidad Nacional Autónoma de México, Tlalnepantla, México

Corresponding author: Armando T. Wakida-Kusunoki (armandowakida@yahoo.com.mx)

ABSTRACT. An abnormal embryo (male of 465 mm total length) and 13 other embryos were removed from a pregnant female bull shark (*Carcharhinus leucas*) caught in coastal waters between the Grijalva River and Terminos Lagoon in the southwestern Gulf of Mexico. The first record of synophthalmia and leucism in the bull shark is presented. The shark cyclopia case is reviewed.

Keywords: *Carcharhinus leucas*; abnormality; malformation; Elasmobranchii; bull shark; Gulf of Mexico

Leucism is a phenotypic mutation that occurs with the absence of color in part of the body, preserving the normal color of the eyes (Lutz 2001). It has been hypothesized to be more detrimental to benthic fishes' survival than pelagic ones (De Jesus-Roldán 1990). Leucism has been linked to genetic alterations in pigment production (Bejarano-Álvarez & Galván-Magaña 2013) and inbreeding in isolated populations (Sanabria et al. 2010), environmental stress and intense fishing pressure (Bruckner & Coward 2018). Other anthropic factors to consider are organochlorines and polychlorinated benzyl, which are components of persistent organic pollutants widely known as teratogenic and carcinogenic (Martínez-Villa et al. 2014), as has been observed in cases of albinism with cyclopia in sea turtles (Bárceñas & Maldonado 2009).

Cyclopia manifests itself with the presence of a single or two partially separated eyes within a single ocular orbit with a proboscis (nasal structures) over the eye (Garzosi & Barkay 1985). Cyclopia has been described as one of the most lethal congenital malformations. This malformation presents different

degrees of cranial deformity. The mildest cyclopia is synophthalmia, in which some elements of two eyes are fused and form a single eye in the middle region of the forehead (Cohen 1982, Nourani et al. 2014). Hypoxic stress is one of the best-known causes of anophthalmia and cyclopia, as observed experimentally in zebrafish (*Brachydanio rerio*), mummichog (*Fundulus heteroclitus*), and mammals, including humans (Ingalls & Philbrook 1958). It has also been observed that overcrowding in aquaculture tanks causes neuroskeletal malformations, among which cyclopia stands out (Baltazar & Palacios 2020).

The processes that lead to cyclopia cause a slow growth of the prosencephalon, which prevents separation in three planes: 1) sagittal in the cerebral hemispheres, 2) transversal in the telencephalon, and diencephalon, 3) horizontal in the olfactory and optic bulbs, which causes large craniofacial deformations (Cohen et al. 1982), a fatal condition for the development of neonates.

In some cases, cyclopia in elasmobranchs is accompanied by albinism. The species that have been

Table 1. Reported cases of cyclopia in sharks and their possible causes.

Species	Albinism	Vertebral deformity	Locality	Possible cause	Reference
<i>Carcharhinus perezii</i>	No	No	Yucatán México, eastern Tropical Atlantic	Teratogenic mutation in the environment	Bonfil (1989)
<i>Carcharhinus plumbeus</i>	Yes	Yes	Gulf of Gabès (south of Tunisia, Central Mediterranean)	Failure in brain development and pressure from high density and intrauterine competence	Saïdi et al. (2006)
<i>Carcharhinus obscurus</i>	Yes	Yes	Gulf of California, BCS, Mexico	Recessive mutations and multi-factor	Bejarano-Álvarez & Galván-Magaña (2013)
<i>Squatina californica</i>	Yes	No	Gulf of California, BCS, Mexico	Intrauterine congenital malformation, with possible abiotic causes and contaminants	Escobar-Sánchez et al. (2014)
<i>Galeorhinus galeus</i>	No	Yes	Tropical Eastern Atlantic, Canary Islands	Failure in brain development and pressure from high density and intrauterine competence	Ramírez-Amaro et al. (2019)
<i>Carcharhinus leucas</i>	Yes	No	Campeche, México, in the southwestern Gulf of Mexico	Concomitant anthropogenic and natural factors.	This paper

reported with this condition are *Carcharhinus perezii* (Bonfil, 1989), *Carcharhinus plumbeus* (even without development of gill openings, Saïdi et al. 2006), *Prionace glauca*, *Galeorhinus galeus* (Ramírez-Amaro et al. 2019), *Carcharhinus obscurus* (Bejarano-Álvarez & Galván-Magaña 2013), and *Squatina californica* (Escobar-Sánchez et al. 2014). The reports where both abnormalities have been reported in sharks are shown (Table 1).

The bull shark, *Carcharhinus leucas* (Müller & Henle, 1839), is a species of tropical and warm waters, characterized by its preference for brackish waters, mainly after the rains, where the plumes of the rivers and the coast are located, feeding on their prey (Werry et al. 2018, Gaussmann 2021) such as schooling fish (e.g. mullets) that congregate on floating objects (Castro et al. 2002). The species is placental viviparous with litters of up to 14 individuals that at birth measure almost 60 cm of total length (TL) (Compagno 1984, Pirog et al. 2019). *C. leucas* is one of the six main species of sharks that support shark fishing in the Gulf of Mexico, but a substantial decline has been observed from 2007 to 2010 (Marcos-Camacho et al. 2016). In addition, the IUCN included it in the red list in the vulnerable category (Rigby et al. 2021). Non-lethal spinal deformities have been found in this species (Clark 1964, Schwartz 1973, Afonso et al. 2016). The only cranial deformity described in bull sharks is one embryo with bicephaly collected in waters near Florida, USA (Wagner et al. 2013).

The present work describes for the first time a case of synophthalmia (mildest degree of cyclopia) and leucism in a male embryo of 465 mm TL. This embryo

has head deformities and was the smallest of 12 other term embryos (620-750 mm TL) of a female bull shark, *C. leucas* of 2700 mm TL. The mother bull shark was captured in marine waters of the southwestern Gulf of Mexico between the Grijalva River's mouth and Terminos Lagoon and was landed in Progreso, Yucatán. The first time, the synophthalmic specimen was immersed in 96% ethanol by the fisherman. It was processed with 10% formalin for four weeks and, finally, conserved in 96% ethanol and deposited in the Colección Ictiológica Regional UMDI Sisal (Semarnat Yuc-Pec 239-01-11) of the Yucatan Academic Unit, Universidad Nacional Autónoma de Mexico, under the collection number CIRR-541.

Description

The organism has a very light gray color on the back and upper flanks, a white belly, and a marked interdorsal line without this being a dermal fold. The ventral tips of the pectoral and pelvic fins with a very faint dark spot (Fig. 1). The eyes are presented in a single opening very close to the sagittal plane -separated by 0.3 mm-preserving their independence (synophthalmia). The pupils of the eyes are dark (Figs. 2a-b). The head has a coniform proboscis above the ocular opening (Figs. 2a-c), with a subterminal ovoid opening where the nostrils should be located (Fig. 2a). The jaw and gill openings are well-developed as the normal pup of the bull shark, but differ by the subterminal position of the eyes rather than the lateral position of normal individuals (Fig. 3). Other abnormalities were not observed. The morphometric measurements of this specimen are presented in Table 2. This table compares the average and standard

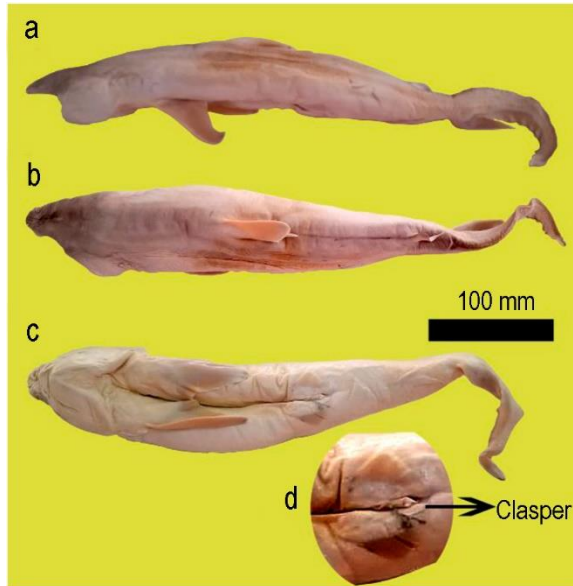


Figure 1. A complete view of the male embryo of *Carcharhinus leucas*. a) Left back, b) dorsal, c) ventral, and d) clasper. Photographs by A.T. Wakida-Kusunoki.

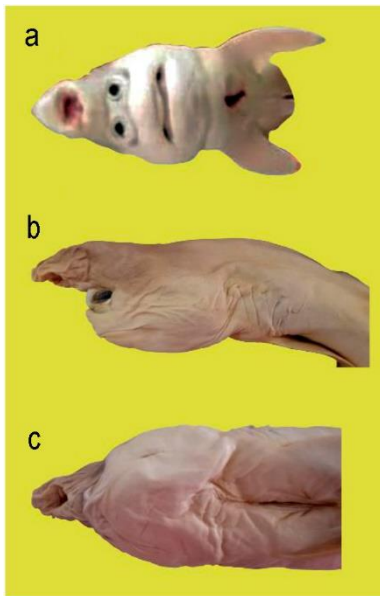


Figure 2. View of the head of the male embryo of *Carcharhinus leucas*. a) Front view, b) left side view, and c) ventral view. Photographs by A.T. Wakida-Kusunoki.

deviation of the morphometrics percentage of six embryos (three females and three males) from a female of 250 cm TL, captured on July 02, 2022, in coastal waters near Ciudad del Carmen, Campeche. In 72 of 93 morphometrics, great differences are observed, mainly caused by the proboscis on the anomalous specimen,

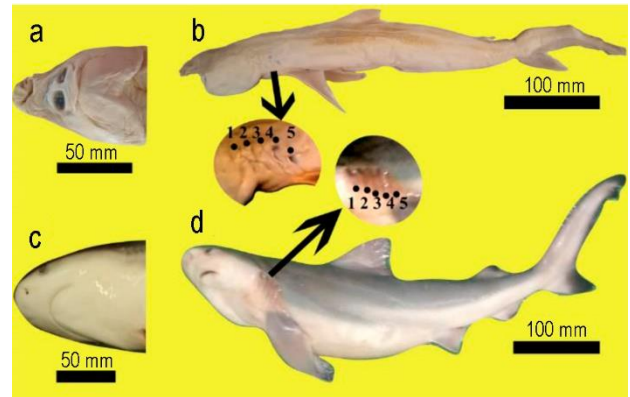


Figure 3. Comparative view of the abnormal male embryo with a normal female embryo of *Carcharhinus leucas*. a) Ventral head view of an abnormal shark, b) left side view with the open-gills zoom of an abnormal shark, c) ventral head view of a normal shark, and d) left side view with the open-gills zoom of a normal shark. Photographs (a-b) by A.T. Wakida-Kusunoki, photographs (c-d) by Andrés Irigoyen-Solis.

besides the disposition of the nostrils in the cyclopean individual and the eyes in a subterminal position (Fig. 3).

It has been proposed that skeletal malformations in sharks may be due to multifactorial causes, some attributable to genetics (congenital or hereditary), failure in embryonic development, overpopulation and intrauterine competition, inbreeding, malnutrition, parasites, infections, lesions (Heupel et al. 1999, Thorburn & Morgan 2004, Saïdi et al. 2006, Escobar-Sánchez et al. 2014). Al-Hassan et al. (2000) consider pollution by polycyclic aromatic hydrocarbons as a possible cause of malformations. Irigoyen-Arredondo et al. (2017) speculate that, in the case of leucism, anthropogenic stress (fishing, navigation routes, pollution) may be part of the causes, and it is important to consider it in this case because albinism and leucism in some cases accompany cyclopia.

The possible influence of concomitant factors, both natural and anthropogenic, that affect cranial-encephalic development cannot be ruled out since they cannot be easily evaluated in the wild. In addition, this area is one where more reports of abnormalities in fish species have been reported in Mexico (Wakida-Kusunoki & Amador-del Ángel 2013, Wakida-Kusunoki 2015, Mendoza-Carranza et al. 2016, Guerra-Jiménez & Lara-Mendoza 2018, Lara-Mendoza & Guerra-Jiménez 2020).

Table 2. Morphometric measurements of the synophthalmia and leucism embryo of *Carcharhinus leucas* in the southwestern Gulf of Mexico compared with six pups of coastal water near Ciudad del Carmen, Campeche: females of 620, 620, 640 mm total length (TL) and males 580, 630 and 650 mm of TL. SD: standard deviation.

Morphometrics	Normal pup		Abnormal embryo	
	Average (%)	SD	Measures (mm)	Average (%)
Total length in mm	523.3	24.2	465	
Measures as a percentage of total length				
Fork length	80.4	1.7	375	81
Pre-caudal length	68.7	9.3	340	73
Pre-second dorsal length	59.3	1.7	305	66
Pre-first dorsal length	24.3	3.0	159	34
Head length	18.6	2.4	102	22
Pre-pectoral length	15.3	1.4	104	22
Pre-pelvic length	44.4	3.5	220	47
Snout-vent length	49.8	2.7	230	49
Pre-anal length	59.5	2.4	293	63
Inter-dorsal space	19.6	0.2	92	20
Pectoral-pelvic space	25.6	1.2	108	23
Dorsal-caudal space	7.3	0.5	23.4	5
Pelvic-anal space	9.9	0.7	68	15
Anal-caudal space	6.2	0.3	29	6
Pelvic-caudal space	21.0	1.1	102	22
Vent-caudal length	42.1	2.7	190	41
Pectoral base	5.5	0.2	23.6	5
Pectoral anterior margin	17.5	0.9	84	18
Pectoral inner margin	7.1	0.3	28	6
Pectoral posterior margin	8.4	0.4	54.7	12
Pectoral height	14.4	0.9	73.5	16
Dorsal caudal margin	27.6	0.9	133.1	29
Pre-ventral caudal margin	11.7	0.9	55	12
Upper post-ventral caudal margin	14.5	0.6	69.1	15
Lower post-ventral caudal margin	5.2	0.3	26	6
Caudal fork width	7.7	0.7	37	8
Caudal fork length	8.6	0.9	32	7
Sub-terminal caudal margin	2.5	0.4	15	3
Sub-terminal caudal margin	3.4	0.4	25	5
Terminal caudal margin	6.2	0.9	30	6
Terminal caudal lobe	6.2	0.2	60	13
First dorsal length	17.9	2.5	63	14
First dorsal anterior margin	15.0	0.6	75	16
First dorsal base	14.6	1.3	37	8
First dorsal height	7.6	0.5	23	5
First dorsal inner margin	4.6	0.2	45	10
First dorsal posterior margin	6.6	0.4	34	7
Second dorsal length	8.0	0.6	14	3
Second dorsal anterior margin	5.5	0.3	10	2
Second dorsal base	5.1	0.6	16	3
Second dorsal height	3.1	0.1	24	5
Second dorsal inner margin	2.8	0.4	22	5
Second dorsal posterior margin	3.8	0.3	30	6
Pelvic length	8.6	0.4	18	4
Pelvic anterior margin	6.6	0.7	25	5
Pelvic base	4.8	0.3	16	3
Pelvic height	4.9	0.2	15	3
Pelvic inner margin length	4.3	0.7	25	5

Continuation

Morphometrics	Normal pup		Abnormal embryo	
	Average (%)	SD	Measures (mm)	Average (%)
Pelvic posterior margin length	4.7	0.3	98.5	21
Head length	20.2	1.2	50	11
Trunk height	14.4	1.5	51.4	11
Abdomen height	17.2	0.4	51	11
Tail height	8.4	3.8	48	10
Caudal peduncle height	4.6	0.3	17.3	4
Anal length	8.4	0.7	23	5
Anal anterior margin	8.0	0.3	12	3
Anal base	5.6	0.2	15	3
Anal height	3.9	0.6	21	5
Anal inner margin	3.4	0.2	20	4
Anal posterior margin	5.7	0.4	49	11
First dorsal midpoint-pelvic origin	16.9	1.8	44.5	10
Pelvic midpoint-first dorsal insertion	11.9	1.7	58	12
Pelvic midpoint-second dorsal origin	8.4	0.8	36	8
Second dorsal origin-anal origin	2.6	0.2	15	3
Second dorsal insertion-anal insertion	2.7	0.2	14	3
Clasper outer length	4.5	0.9	15	3
Clasper inner length	5.7	0.9	21.6	5
Clasper base width	1.0	0.1	3.4	1
Head width	15.1	0.8	63	14
Trunk width	16.0	2.8	70	15
Abdomen width	16.3	1.6	69.3	15
Tail width	9.0	0.1	42	9
Caudal peduncle width	5.0	0.6	23.5	5
Measures as a percentage of head length				
Pre-orbital length	3.6	0.3	25	24.5
Eye length	1.2	0.1	10	9.8
Eye height	1.2	0.1	15	14.7
Sub-ocular pocket length	1.2	0.1	5.4	5.3
Inter orbital space	12.7	0.9	0.3	0.3
Pre oral length	4.8	0.3	22	21.6
Nostril width	0.8	0.1	Absent	
Internarial space	1.8	0.2	Absent	
Anterior nasal flap length	0.6	0.1	Absent	
Mouth length	2.4	0.2	27	26.5
Mouth width	3.2	0.1	46	45.1
Lower labial furrow length	1.3	0.2	3	2.9
Pre-branchial length	13.6	1.8	74	72.5
Inter gill length	4.4	0.2	31	30.4
First-gill slit height	2.8	0.3	15	14.7
Second-gill slit height	2.6	0.2	16	15.7
Third-gill slit height	3.1	0.3	19	18.6
Fourth-gill slit height	3.3	0.4	15	14.7
Fifth-gill slit height	3.5	0.6	17	16.7

ACKNOWLEDGMENTS

The authors thank Juan Manuel González Morales, a worker at the Quiñonez Freezer in Progreso Yucatán,

for facilitating the shark specimen, and Andrés Irigoyen-Solís, member of Grupo de Investigadores Libres Sphyrna, for supporting in obtaining the specimen and the photograph of normal pup bull shark.

REFERENCES

- Afonso, A.S., Niella, Y.V., Cavalcanti, E., Andrade, M.B., Afonso, J.S., Pinto, P.S. & Hazin, F.H.V. 2016. Spinal deformities in free-ranging bull sharks, *Carcharhinus leucas* (Müller & Henle, 1839), from the western South Atlantic Ocean. *Journal Applied Ichthyology*, 32: 1-4. doi: 10.1111/jai.13125
- Al-Hassan, J.M., Afzal, M., Rao, C.V.N. & Fayad, S. 2000. Petroleum hydrocarbon pollution in sharks in the Arabian Gulf. *Bulletin of Environmental Contamination and Toxicology*, 65: 391-398. doi: 10.1007/s001280000140
- Baltazar, G.P.M. & Palacios, L.J. 2020. Malformaciones congénitas en larvas de *Oreochromis niloticus* durante la incubación en criaderos. *Revista de Investigación Veterinaria del Perú*, 31: e17342. doi: 1015371/riveo.v31:4.17342
- Bárceñas, I.A. & Maldonado, G. 2009. Malformaciones en embriones y neonatos de tortuga golfina (*Lepidochelys olivacea*) en Nuevo Vallarta, Nayarit, México. *Veterinaria México*, 40: 371-380.
- Bejarano-Álvarez, O.M. & Galván-Magaña, F. 2013. First report of an embryonic dusky shark (*Carcharhinus obscurus*) with cyclopia and other abnormalities. *Marine Biodiversity Records*, 6: 1-4. doi: 10.1017/S1755267212001236
- Bonfil, R. 1989. An abnormal embryo of the reef shark, *Carcharhinus perezii* (Poey), from Yucatan, Mexico. *Northeast Gulf Science*, 10: 153-155. doi: 10.18785/negs.1002.08
- Bruckner, A.W. & Coward, G. 2018. Unusual occurrence of abnormal skin pigmentation in blacktip reef sharks (*Carcharhinus melanopterus*). *Coral Reefs*, 37: 389. doi: 10.1007/s00338-018-1663-4
- Castro, J.J., Santiago, J.A. & Santana-Ortega, A.T. 2002. Point of view. A general theory on fish aggregation to floating objects: an alternative to the meeting point hypothesis. *Reviews in Fish Biology and Fisheries*, 11: 255-277.
- Clark, E. 1964. Spinal deformity noted in bull shark. *Underwater Naturalist*, 2: 25-28.
- Cohen, M.M. 1982. An update on the holoprosencephalic disorders. *Journal of Pediatrics*, 101: 865-869. doi: 10.1016/s0022-3476(82)80349-1
- Compagno, L.J.V. 1984. FAO species catalogue. Vol. 4. Sharks of the world. An annotated and illustrated catalogue of shark species known to date. Part 2 - Carcharhiniformes. FAO Fisheries Synopsis, 125: 251-655.
- De Jesus-Roldán, M. 1990. An albino bat ray *Myliobatis californica*, from the Pacific coast of Baja California Sur, Mexico. *California Fish and Game*, 76: 126-127.
- Escobar-Sánchez, O., Moreno-Sánchez, X.G., Aguilar-Cruz, C.A. & Abitia-Cárdenas, L.A. 2014. First case of synophthalmia and albinism in the Pacific angel shark *Squatina californica*. *Journal of Fish Biology*, 85: 1-8. doi: 10.1111/jfb.12412
- Garzozzi, A.J. & Barkay, S. 1985. Case of true cyclopia. *British Journal of Ophthalmology*, 69: 307-311. doi: 10.1136/bjo.69.4.307
- Gaussmann, P. 2021. Synopsis of global fresh and brackish water occurrences of the bull shark *Carcharhinus leucas* Valenciennes, 1839 (Pisces: Carcharhinidae), with comments on distribution and habitat use. *Integrative Systematics*, 4. doi: 10.18476/2021.423083
- Guerra-Jiménez, L.A. & Lara-Mendoza, R.E. 2018. Primer registro de albinismo en el bagre boca chica *Ariopsis felis* (Siluriformes: Ariidae) del sureste del Golfo de México. *Revista Ciencias Marinas y Costeras*, 10: 39-46. doi: 10.15359/revmar10-1.3
- Heupel, M.R., Simpfendorfer, C.A. & Bennett, M.B. 1999. Skeletal deformities in elasmobranchs from Australian waters. *Journal of Fish Biology*, 54: 1111-1115. doi: 10.1111/j.1095-8649.1999.tb00861.x
- Ingalls, T.H. & Philbrook, F.R. 1958. Monstrosities induced by hypoxia. *The New England Journal of Medicine*, 18: 558-564. doi: 10.1056/NEJM195809182591202
- Irigoyen-Arredondo, M.S., Escobar-Sánchez, O., Abitia-Cardenas, L.A., Moreno-Sanchez, X.G. & Palacios-Salgado, D.S. 2017. Incidence of xanthism in the leopard grouper *Mycteroperca rosacea* (Perciformes: Serranidae) in the Gulf of California. *Marine Biodiversity*, 48: 2255-2258. doi: 10.1007/s12526-017-0753-9
- Lara-Mendoza, R.E. & Guerra-Jiménez, L.A. 2020. Record of albinism in the smooth butterfly ray *Gymnura micrura* (Rajiformes, Gymnuridae) from the southeastern Gulf of Mexico. *Pan-American Journal of Aquatic Sciences*, 15: 33-38.
- Lutz, G.C. 2001. Practical genetics for aquaculture. Blackwell Science, Oxford.
- Marcos-Camacho, S.A., Nalesso, E., Caamal-Madrigal, J.A. & Fulton, S. 2016. Caracterización de la pesquería de tiburón en el norte de Quintana Roo, México. *Ciencia Pesquera*, 24: 153-156.
- Martínez-Villa, G., Betancourt-Lozano, M., Aguilar-Zárate, G., Ruelas-Inzunza, J., Anislado-Tolentino, V.,

- Cerdenares, G. & González, G. 2014. Contenido de plaguicidas organoclorados en varios peces depredadores de la costa de Oaxaca y evaluación del riesgo de exposición por consumo en la salud humana. In: Botello, A.V., Páez-Osuna, F., Méndez-Rodríguez, L., Betancourt-Lozano, M., Álvarez-Borrego, S. & Lara-Lara, R. (Eds.). Pacífico mexicano. Contaminación e impacto ambiental: diagnóstico y tendencias. UAC, UNAM-ICMYL, CIAD-MAZATLAN, CIBNOR, CICESE, Ciudad de México, pp. 169- 209.
- Mendoza-Carranza, M., Santiago-Alarcón, D., Pérez-Jiménez, J.C. & Hernández-Lazo, C.C. 2016. Eyeless morphotype in the southern stingray (*Dasyatis americana*): a non-lethal and frequent abnormality from the southern Gulf of Mexico. *Latin American Journal of Aquatic Research*, 44: 460-469. doi: 10.3856/vol44-issue3-fulltext-4
- Nourani, H., Karimi, I. & Rajabi-Vardanjani, H. 2014. Synophthalmia in a Holstein cross calf. *Veterinary Research Forum: An International Quarterly Journal*, 5: 333-335.
- Pirog, A. & Magalon, H., Poirout, T. & Jaquemet, S. 2019. Reproductive biology, multiple paternity and polyandry of the bull shark *Carcharhinus leucas*. *Journal of Fish Biology*, 95. doi: 10.1111/jfb.14118.
- Ramírez-Amaro, S., Fernández-Peralta, L., Serna, F. & Puerto, M.A. 2019. Abnormalities in two shark species, the blue shark, *Prionace glauca*, and the school shark, *Galeorhinus galeus* (Elasmobranchii: Carcharhiniformes), from the Canary Islands, eastern tropical Atlantic. *Acta Ichthyologica et Piscatoria*, 49: 295-303. doi: 10.3750/AIEP/02615
- Rigby, C.L., Espinoza, M., Derrick, D., Pacoureaux, N. & Dicken, M. 2021. *Carcharhinus leucas*. The IUCN Red List of Threatened Species, 2021: e.T39372A2910670. doi: 10.2305/IUCN.UK.2021-2.RLTS.T39372A2910670.en
- Saïdi, B., Bradaï, M.N., Marouani, S., Guelorget, O. & Capapé, C. 2006. Atypical characteristics of an albino embryo of *Carcharhinus plumbeus* (Chondrichthyes: Carcharhinidae) from the Gulf of Gabés (southern Tunisia, central Mediterranean). *Acta Adriatica*, 47: 167-174.
- Sanabria, E.A., Quiroga, L.B. & Laspiur, A. 2010. First record of partial albinism and scoliosis in *Odontophrynus occidentalis* tadpoles (Anura: Cycloramphidae). *Brazilian Archives of Biology and Technology*, 53: 641-642. doi: 10.1590/S1516-8913201000300019
- Schwartz, F.J. 1973. Spinal and cranial deformities in the elasmobranchs *Carcharhinus leucas*, *Squalus acanthias*, and *Carcharhinus milberti*. *Journal of the Elisha Mitchell Scientific Society*, 89: 74-77.
- Thorburn, D.C. & Morgan, D.L. 2004. The northern river shark *Glyphis* sp. C (Carcharhinidae) discovered in Western Australia. *Zootaxa*, 685: 1-8. doi: 10.11646/zootaxa.685.1.1
- Wagner, C.M., Rice, P.H. & Pease, A.P. 2013. First record of dicephalia in a bull shark *Carcharhinus leucas* (Chondrichthyes: Carcharhinidae) foetus from the Gulf of Mexico, USA. *Journal of Fish Biology*, 82: 1419-1422. doi: 10.1111/jfb.12064
- Wakida-Kusunoki, A.T. 2015. First record of total albinism in southern stingray *Dasyatis americana*. *Revista de Biología Marina y Oceanografía*, 50: 135-139. doi: 10.4067/S0718-19572015000100011
- Wakida-Kusunoki, A.T. & Amador-del Ángel, L.E. 2013. First record of albinism in gafftopsail catfish *Bagre marinus* (Pisces: Ariidae) from southeast Mexico. *Revista de Biología Marina y Oceanografía*, 48: 203-206. doi: 10.4067/S0718-19572013000100019
- Werry, J.M., Sumpton, W., Otway, N.M., Lee, S.Y., Haig, J.A. & Mayer, D.G. 2018. Rainfall and sea surface temperature: key drivers for occurrence of bull shark, *Carcharhinus leucas*, in beach areas. *Global Ecology and Conservation*, 15: e00430. doi: 10.1016/j.gecco.2018.e00430

Received: January 21, 2022; Accepted: August 21, 2022